

# www.simonmoyes.com

Select Language ▾

## Simon Moyes

Consultant Orthopaedic Surgeon



HOME TREATMENT ABOUT SIMON LOCATIONS TESTIMONIALS PRESS CONTACT LINKS



Simon Moyes Consultant Orthopaedic Surgeon

### Welcome from Simon Moyes

Simon specialises in arthroscopic and minimally invasive treatment for problems of the knee, shoulder, foot and ankle

Simon Moyes specialises in keyhole – or arthroscopic – surgery. This is a highly sophisticated, minimally invasive technique which means you spend less time in hospital and you are more likely to have a quick recovery.

- ➔ [Click here to find out more about Simon](#)
- ➔ [More about Simon's weekly diary](#)

twitter 1st Sep 2010 Consulting at The Wellington

#### ➔ Treatment Areas

Mr Simon Moyes offers surgical treatment for problems in these areas of the body :

Knee	Shoulder	Foot	Ankle
			

#### ➔ Treatment Query /Search

Go straight to the specific condition you are looking for by using the drop down below:

Specific condition ▾

#### ➔ Ankle Arthroscopy site

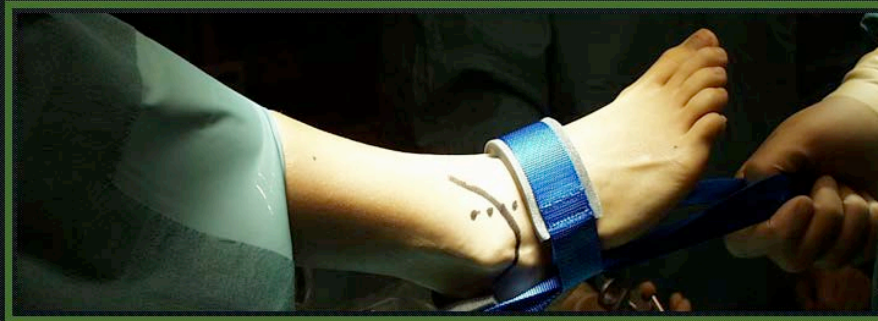

Enquiry Line +44 (0)207 323 0040

Simon Moyes 2006 | sitemap | disclaimer

# www.ankle-arthroscopy.co.uk

## Ankle Arthroscopy

[HOME](#)[PATIENTS' SITE](#)[SURGEONS' SITE](#)[VIDEOS](#)[ABOUT SIMON MOYES](#)[CONTACT](#)[LINKS](#)

### Ankle Arthroscopy Website

Simon Moyes specialises in keyhole – or arthroscopic – surgery. This site is dedicated to conditions of the ankle joint that are treated by Simon. Patients can find all the information they need about some of the more common ankle problems, while surgeons and medical professionals can find an up-to-date medical resource for those involved in or studying ankle arthroscopy.

#### Quick Search

Go straight to the specific page you are looking for by using the drop down below:

#### Patients' Site

An outline of common ankle problems, with information about how the injury / ailment feels, what surgery is likely and the projected recovery time.

[➤ Click here for the Patients' Site](#)

#### Surgeons' Site

An in-depth resource about all aspects of ankle arthroscopy for medical professionals. Contains highly-referenced documentation of the procedure, citing examples from the early history to current findings.

[➤ Click here for the Surgeons' Site](#)



A photograph of a person's foot and ankle being held by a hand. A blue surgical drape is visible on the left. A blue line is drawn on the skin of the ankle, indicating a surgical incision site. The text 'Foot & Ankle Arthroscopy' is overlaid in the center.

# Foot & Ankle Arthroscopy

Presented by Mr Simon Moyes

# Indications for Ankle Arthroscopy




- Impingement (bone and soft tissue)
- Osteochondral lesions
- Ankle arthrodesis
- Loose bodies
- Ankle instability
- Septic arthritis
- Arthrofibrosis
- Ankle osteoarthritis
- Synovitis
- Fractures

# Setup

- Saline pump or gravity inflow
  - Advantages of pump
    - Hemostasis
    - Visualization
    - Easily adjustable
- Lidocaine with adrenaline into joint and subcutaneous at portals for joint distension and hemostasis



# Instrumentation and Equipment



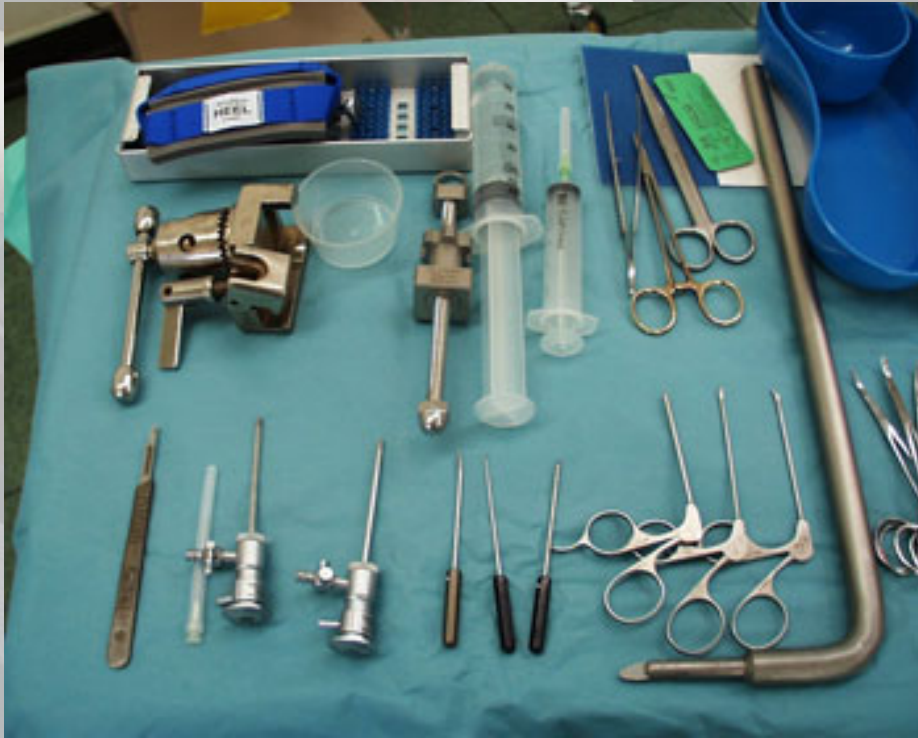## Instrumentation:

- Generally small joint arthroscopy (2.7mm) for foot and ankle
  - Exception: Lot of bony work (e.g. arthrodesis or large spurs), use 4.0mm
  - 2.7mm camera is shorter and easier to manipulate

## Equipment:

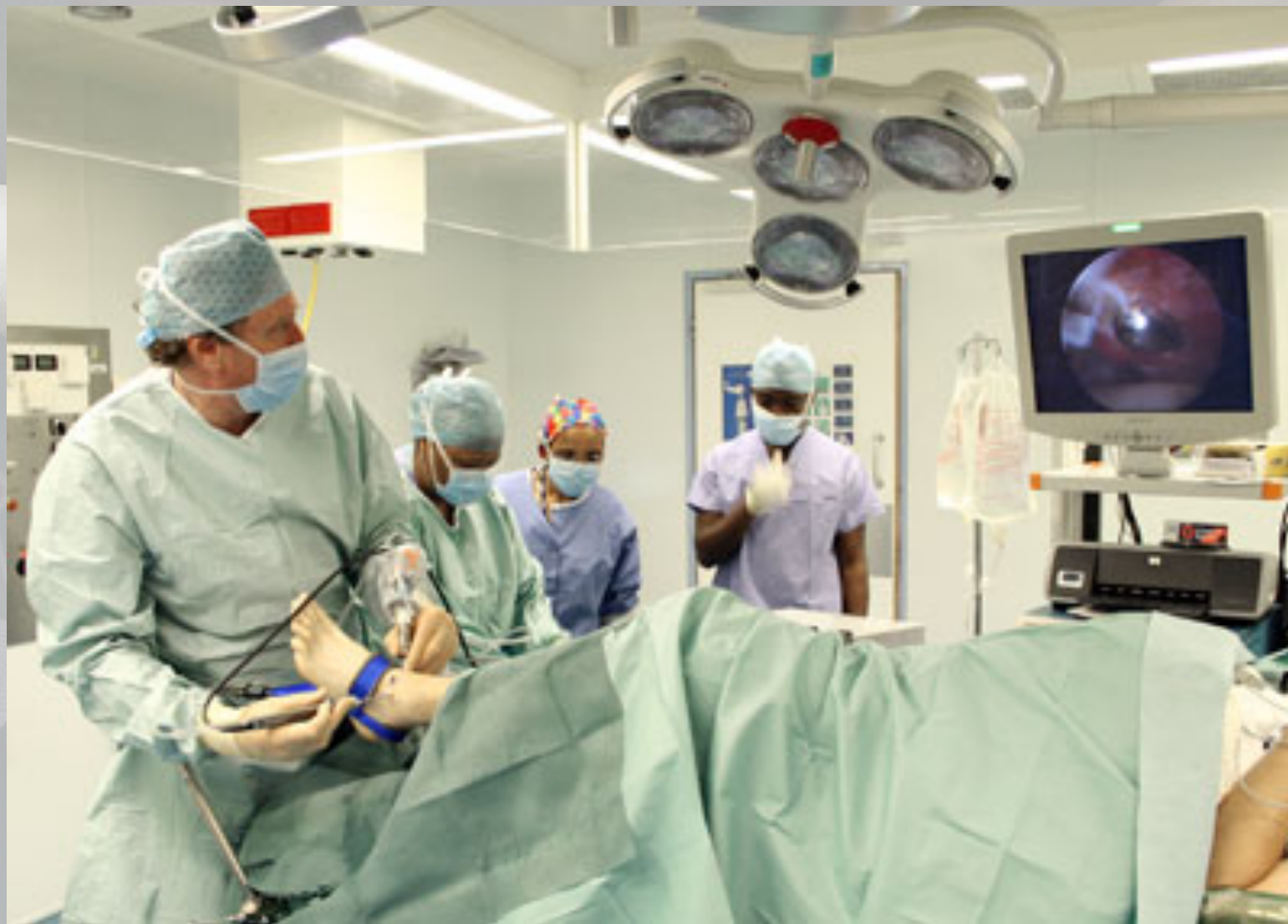- Proximal thigh tourniquet
  - Always have it (occasionally use it)
  - Use very dependant on the case
- Ablator with suction attachment
- Angled and curved instruments

# Instrumentation



- Instrumentation Spinal needles
- Probes
- Dissectors - elevating OCD lesions, ossicles
- Graspers - flat-tipped or pitbull for small or large loose bodies (2.7 - 3.0mm)
- Basket forceps - straight, right and left, up and down angles (2.5 - 3.0mm)
- Knives
- Curettes
- Osteotomes
- Power instruments
- Thigh/Ankle holder
- Aiming jigs

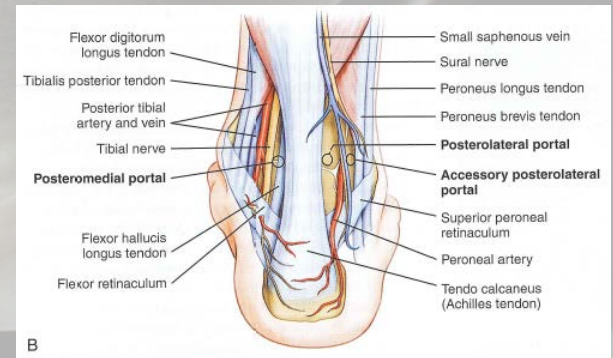
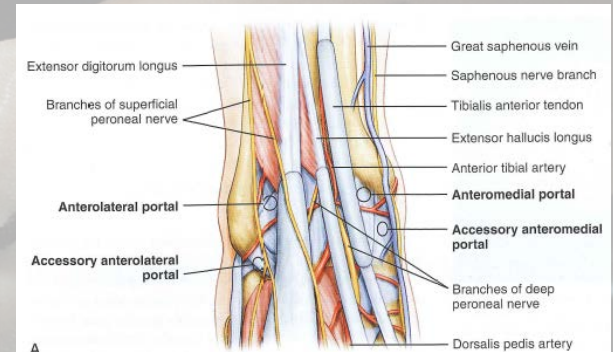




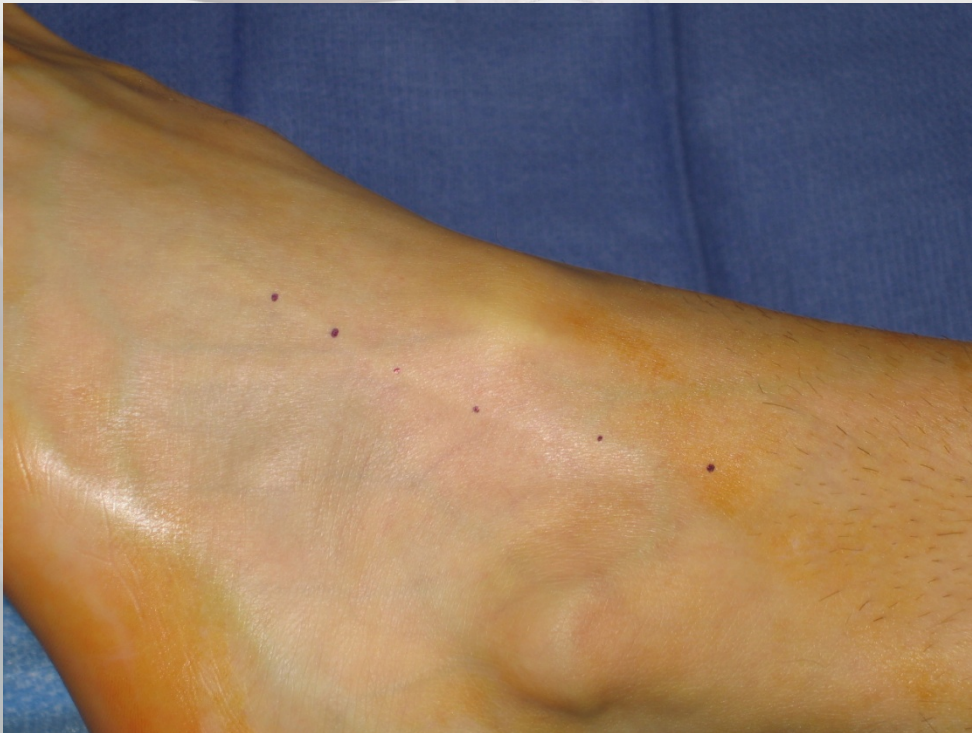

# Portals: Structures at risk

- Anteromedial
  - Saphenous nerve and vein
- Anterolateral
  - Superficial peroneal nerve
- Posterolateral portal
  - Branches of the sural nerve and the small saphenous vein
- Facultative central portal → risk for the deep anterior neurovascular bundle
- 49% of complications from ankle arthroscopy are related to nerve injury at portals



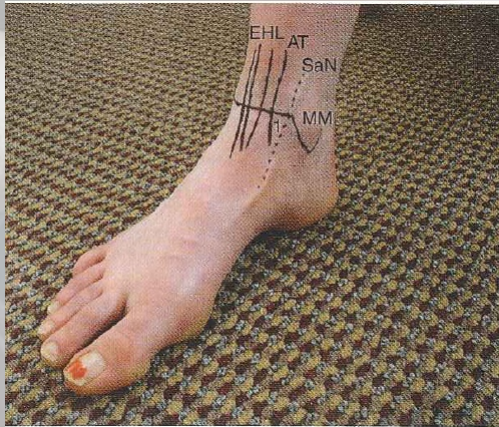
# Identify Superficial Peroneal Nerve whenever possible



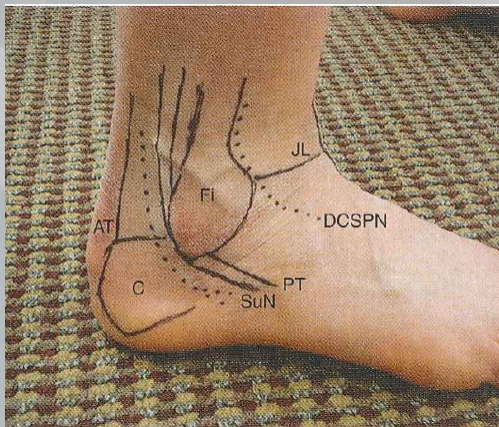
- With 4th toe, plantarflex and invert foot and ankle



# Portals

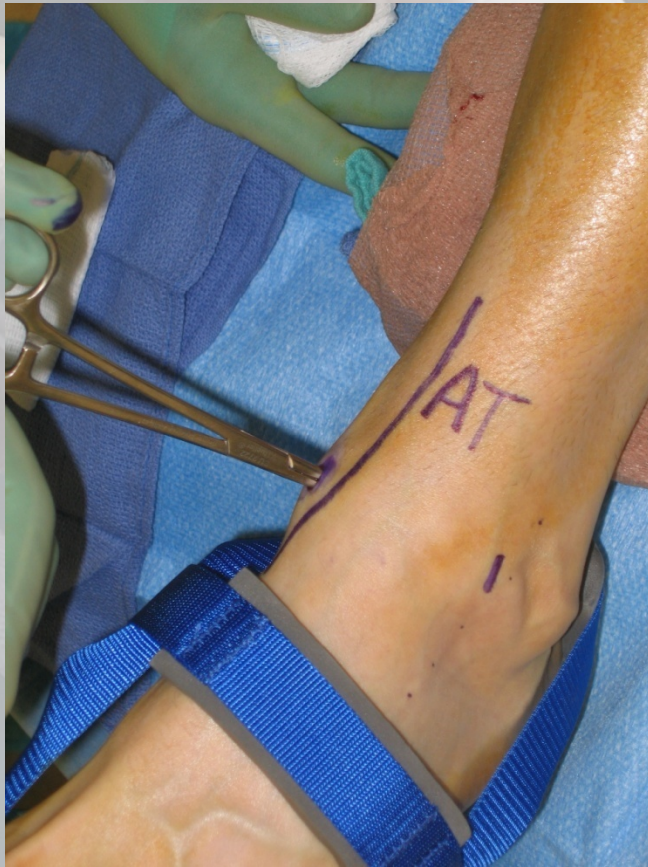

- Anteromedial portal
  - Immediately medial to anterior tibialis
- Identify joint line
  - Via palpation while moving ankle
  - By needle localization
  - X-ray rarely
- Anterolateral
  - Between lateral margin of EDLT and superficial peroneal nerve.

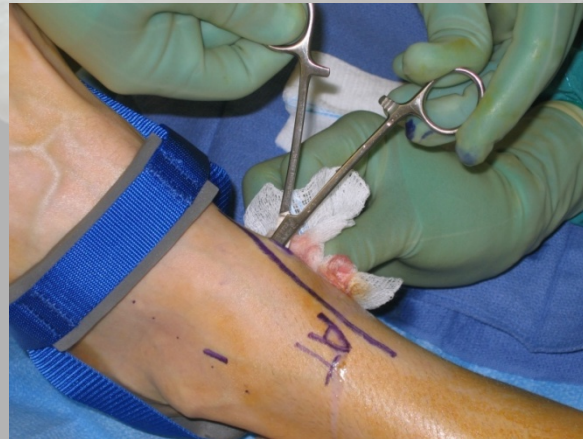



# Portals

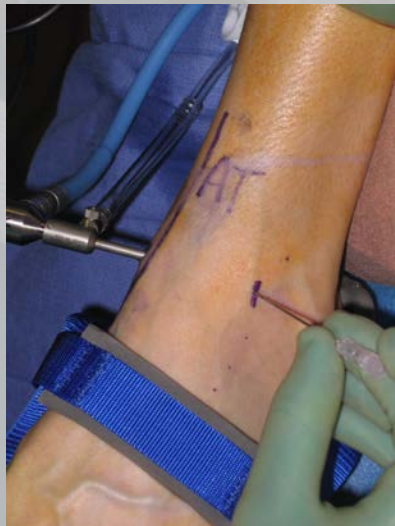
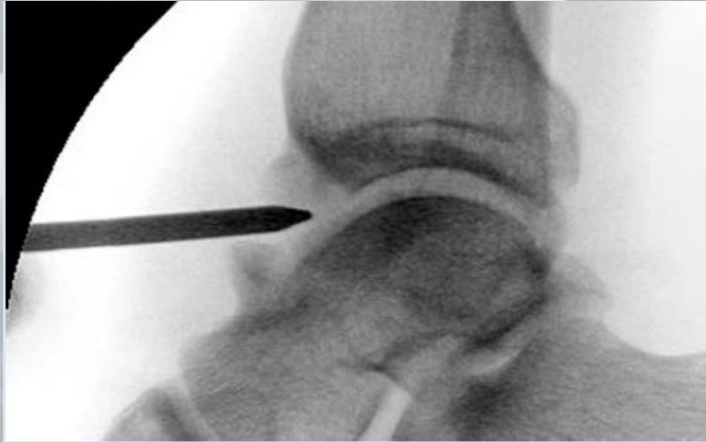
- Nick and spread technique
  - Incise the skin only
  - Insert hemostat into the joint and then spread
  - Create a single track



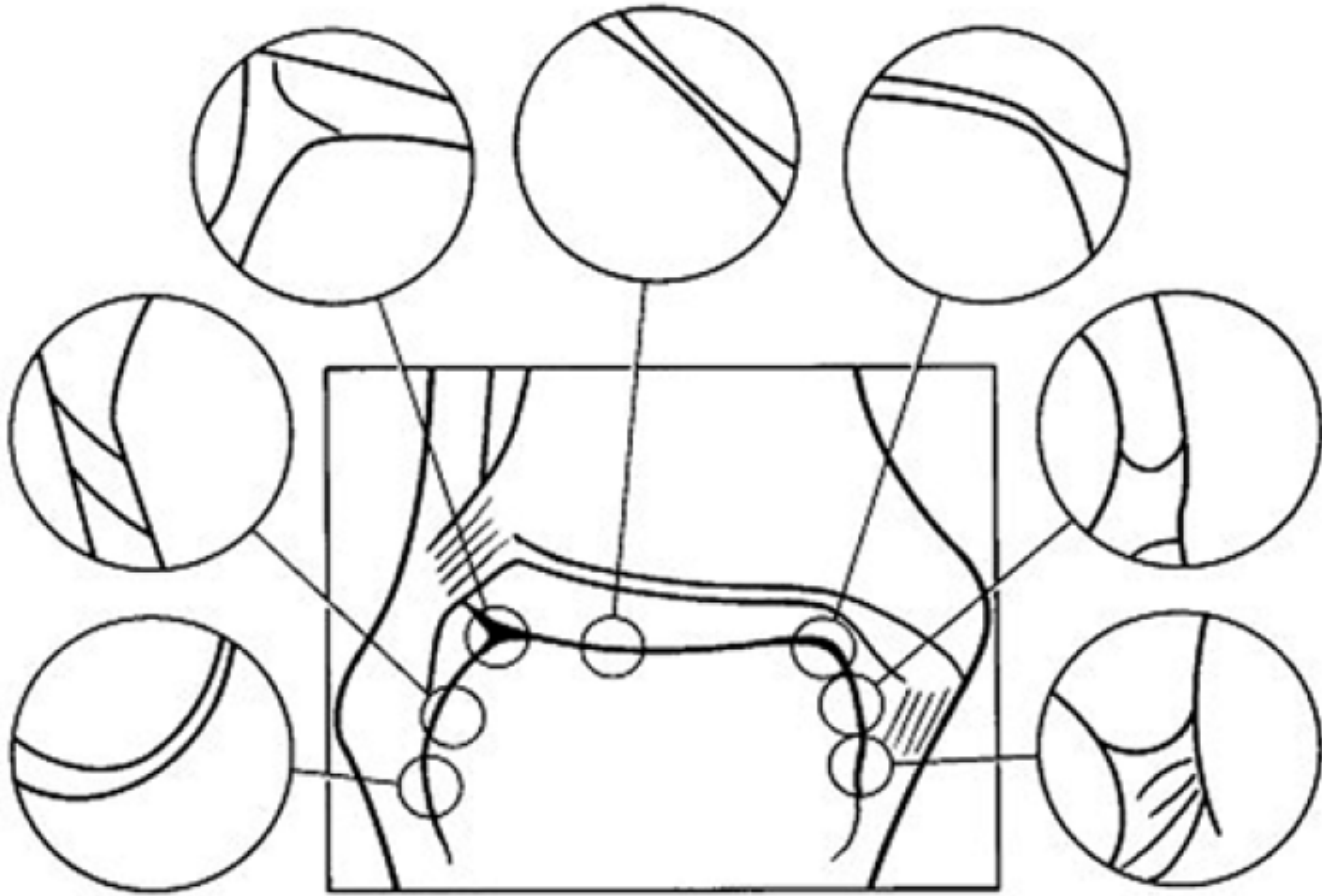


# Portals



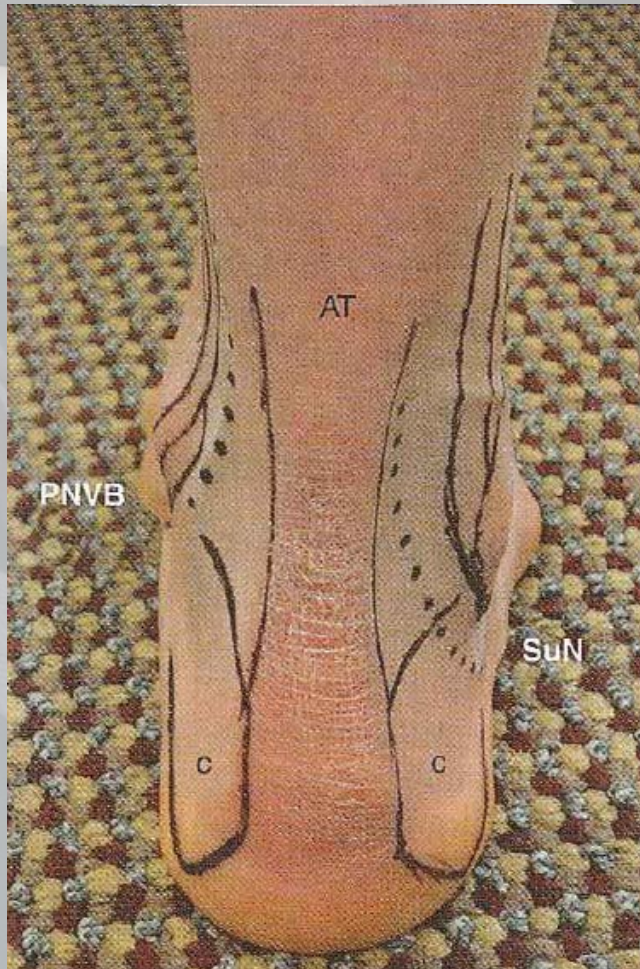
- Establish anteromedial portal first
- All other portals
  - Under direct visualization with needle localization
  - Especially true for osteochondral defects
- If anterolateral portal is established first:
  - Diaphanie is helpful to localize structures at risk: saphena magna vene and branches of saphenal nerve.

# Arthroscopy sightseeing





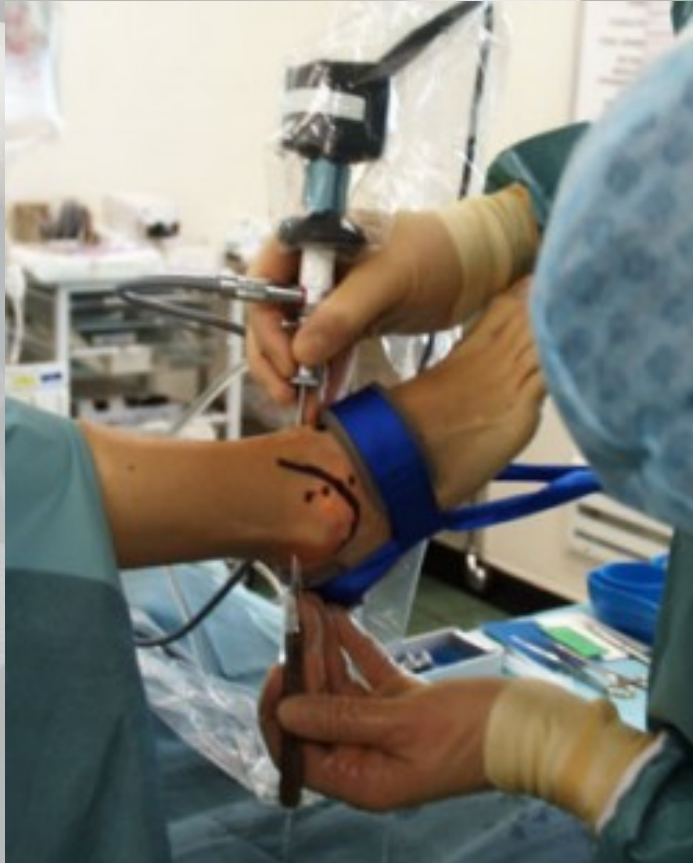# Posterior Portals



- Insert the arthroscope canula with a blunt trocar into the posterolateral portal and direct it toward the great toe. → No vision yet, due to fat obstacles
- Insert the shaver from the posteromedial portal; direct it perpendicular to the arthroscope and slide toward the tip.
- Free space to see the FHLT. Always stay lateral to the FHLT and the medial neurovascular bundle.
- Establish posterior portal for:
  - arthrodesis
  - posterior osteochondral lesions
  - Outflow



# Diagnostic Examination



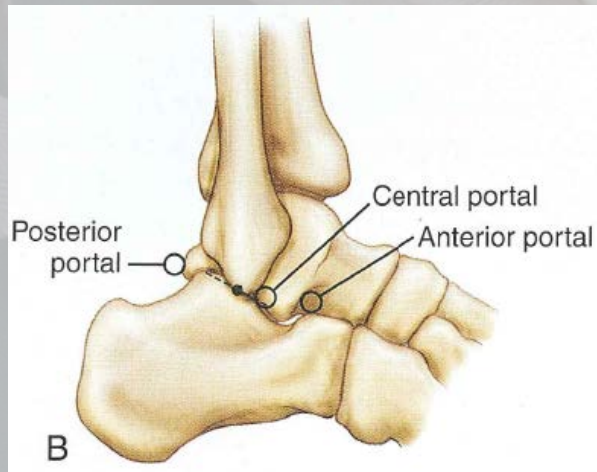
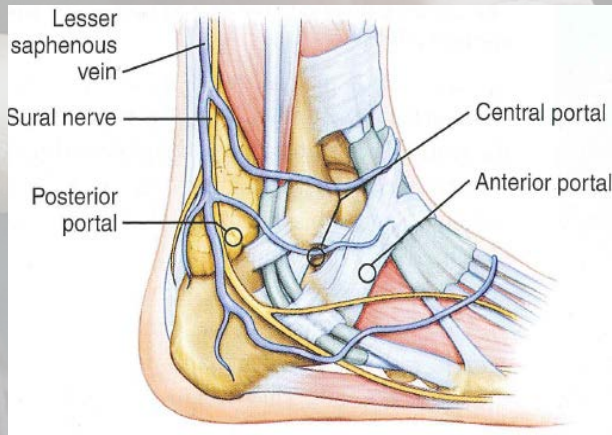
The ankle is first distended with approx 30cc of saline.

- The anteromedial portal is established just medial to tibialis anterior at the level of the joint line carefully avoiding the saphenous nerve.
- Then the anterolateral portal is established using transillumination, avoiding the superficial branch of the lateral popliteal nerve. A full diagnostic inspection of the anterior compartment is then carried out.
- Then the posterolateral portal is made, localising the entry point with a spinal needle. A full inspection of the posterior compartment is then made.

Using these three portals, a full systematic ankle examination can be carried out.



# Subtalar Joint Arthroscopy



- Anterolateral portal:
  - Soft spot of sinus tarsi (2 cm anterior and 1 cm distal to the fibula tip)
- Posterolateral portal:
  - Lateral to achilles tendon 2 cm posterior and 1 cm distal to the fibula tip
- Central portal:
  - Distal and inferior to the lateral malleolus tip and immediately anterior to the peroneal tendon sheath.
- Structures to see:
  - Anterior: Talocalcaneal interosseous ligament
  - Lateral talocalcaneal ligament
  - Calcaneofibular ligament

# Classification anterior impingement and osteoarthritic changes

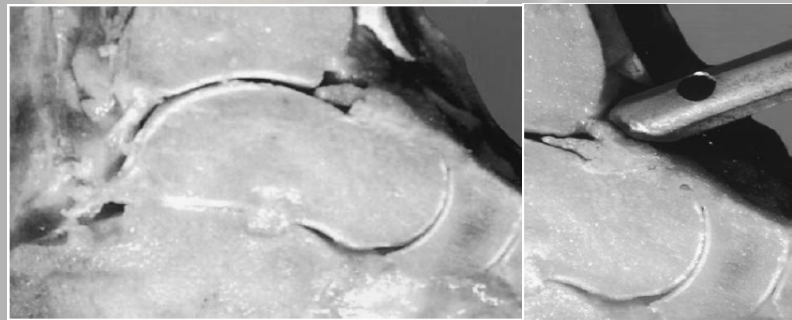
Type	Characteristics
I	Synovial impingement; radiographs: inflammatory reaction up to 3-mm spur formation
II	Osteochondral reaction exostosis; radiographs: osseous spur formation greater than 3 mm; no talar spur is present
III	Significant exostosis with or without fragmentation, secondary spur formation on the dorsum of the talus; often fragmentation osteophytes
IV	Pantalocrural arthritic destruction; radiographs: medial, lateral, or posterior degenerative arthritic changes
Classification of <b>Anterior Ankle Impingement</b> (Scranton PE Jr, McDermott JE. Foot Ankle. 1992;13:125-139)	

Type	Characteristics
I	Normal joint or subchondral sclerosis
II	Osteophytes without joint space narrowing
III	Joint space narrowing with or without osteophytes
IV	Total disappearance or deformation of the joint space
Classification of <b>Osteoarthritic Changes</b> of the Ankle Joint(van Dijk CN, Tol JL, Verheyen CC. Am J Sports Med. 1997;25:737-745)	

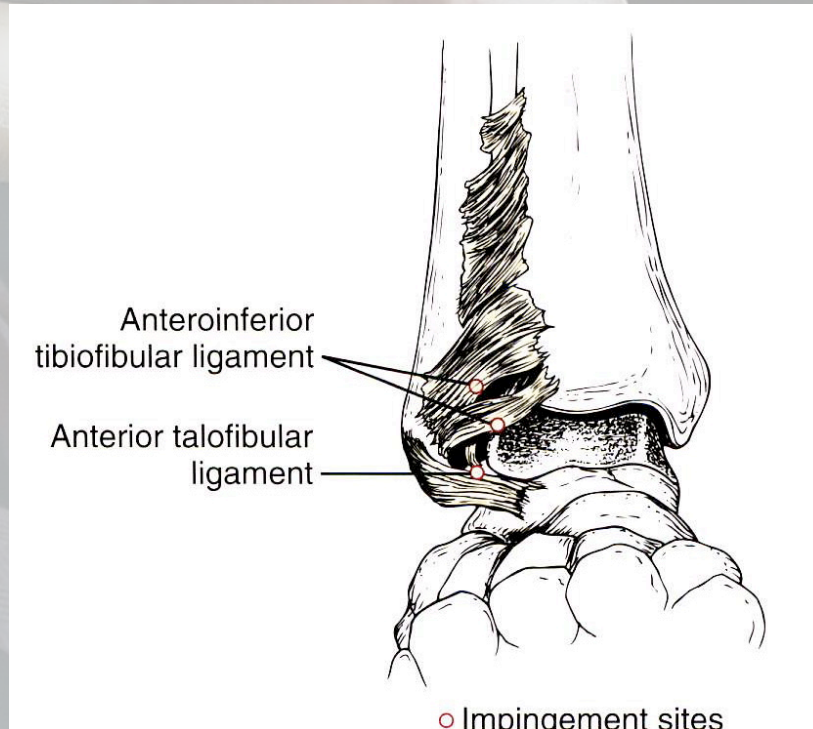


# Anterior Impingement: Physical Examination

- Anterior joint line tenderness
  - Soft tissue typically anterolateral
- Pain with forced dorsiflexion
- Sensitivity of 95% and specificity of 88%  
Molloy, J Bone Joint Surg Br, 2003
- MRI sensitivity of 83% and specificity of 77%



# Sites of soft tissue impingement



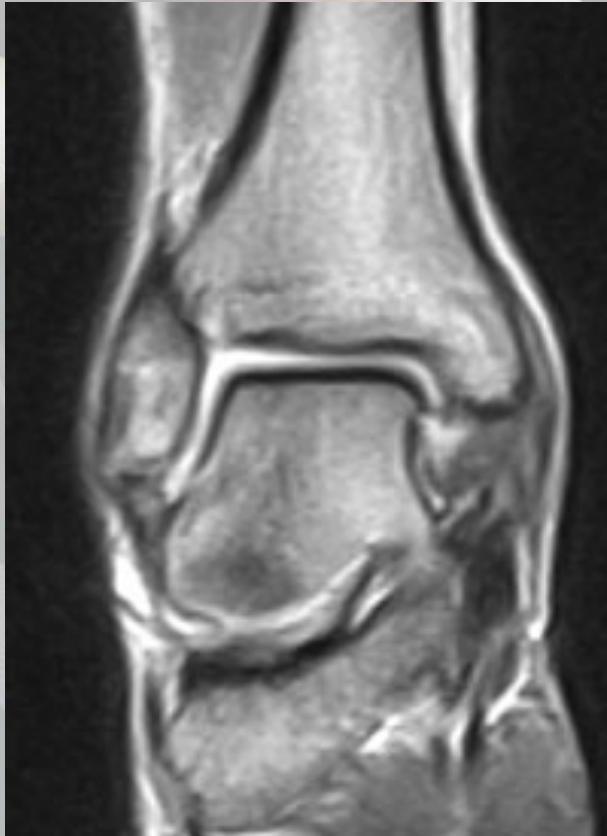- The superior portion of the AITFL
  - 20% of AITFL is intraarticular
- The talofibular ligament at the lateral gutter and talar dome
- The distal portion of the AITFL (Bassett's ligament)



# Soft Tissue Lesions

- Patients with such lesions present with a combination of pain, swelling, tenderness, locking and giving way.
- On examination, one finds a combination of tenderness, wasting, swelling, restricted range and instability.
- Investigations include XR, CT, MRI, arthritis tests. These all may be negative.
- Classification
  - Congenital: plicae / bands
  - Excise
    - Traumatic: sprains, fractures, prior surgery
    - Excise generalised synovitis
    - Excise localised bands
    - Excise meniscoid lesions secondary to impingement

# Impingement



- Lateral ligament injuries are very common, with 1 ankle sprain per 10,000 occurring per day (8). Some 10-50% have some chronic pain (9,10,11).
- Anterolateral impingement is the commonest soft tissue impingement lesion and cause of pain after ankle inversion injury (12). Wolin coined the term 'the meniscoid lesion' for the arthroscopic appearance of the lateral gutter in these patients.
- Arthroscopic treatment is very successful in alleviating chronic pain (13,14,15,16) in 84% both subjectively and objectively. A recent survey by Urg' den M et al (17) in 2005 of 41 patients showed good or excellent results in 37 of the group. Also Henderson et al in 2004 showed similar results for combined anterior and posterior impingement syndrome (18).



# Impingement



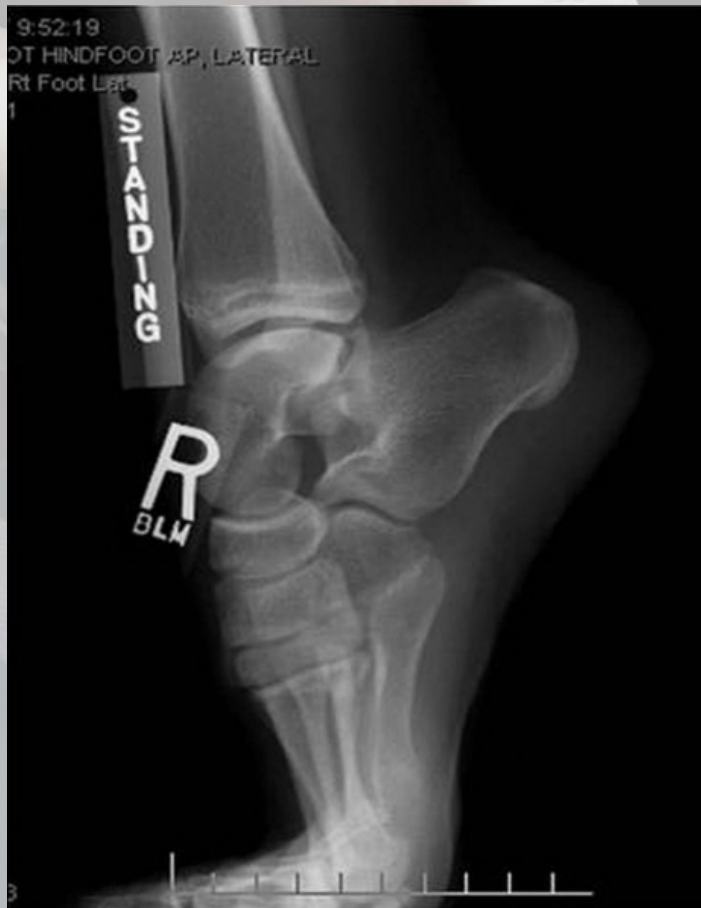- During dorsiflexion of the ankle, the malleoli are separated and the syndesmosis is stressed. Syndesmotic injuries are undoubtedly underestimated (19). Syndesmotic injuries can be diagnosed by a localised tenderness and a positive squeeze test (20, 21) - pressing the tibia and fibula together proximal to the syndesmosis half way up the calf.
- However, Lui T H et al (22) showed in November 2005 that ankle arthroscopy excels stress radiographs in detecting syndesmotic injuries, even though intra-operative x-rays still play an important role in assessing fracture reduction and longitudinal orientation of the syndesmosis. Syndesmotic impingement is also associated with a separate distal fascicle to the anterior talo-fibular ligament (23). The incidence of syndesmotic injury is 3% of all ankle sprains (24).
- Posterior impingement does occur and was first described by Hamilton (25) with posterior 'meniscus' displacing inferiorly. Also a labrum on the posterior lip of the tibia can hypertrophy when injured.

# Inflammatory Lesions

- Rheumatoid arthritis, X-tal synovitis, PVNS and synovial chondromatosis can all affect the ankle.
- Rheumatoid arthritis has been reported to have an arthroscopic cure (26). A 95% synovectomy is possible (27), and early synovectomy is better than late (28).
- PVNS can be treated arthroscopically in the ankle as elsewhere (29).
- Synovial chondromatosis is rare in the ankle, but is treated along standard arthroscopic lines (30).
- Other arthritides such as gonarthritides, Crohn's, gout, chondrocalcinosis are treated with arthroscopic synovectomy (31).
- An article in 2004 in the Journal of Paediatric Orthopaedics (32) of 39 ankles shows successful results with arthroscopic synovectomy for haemophilic arthropathy.

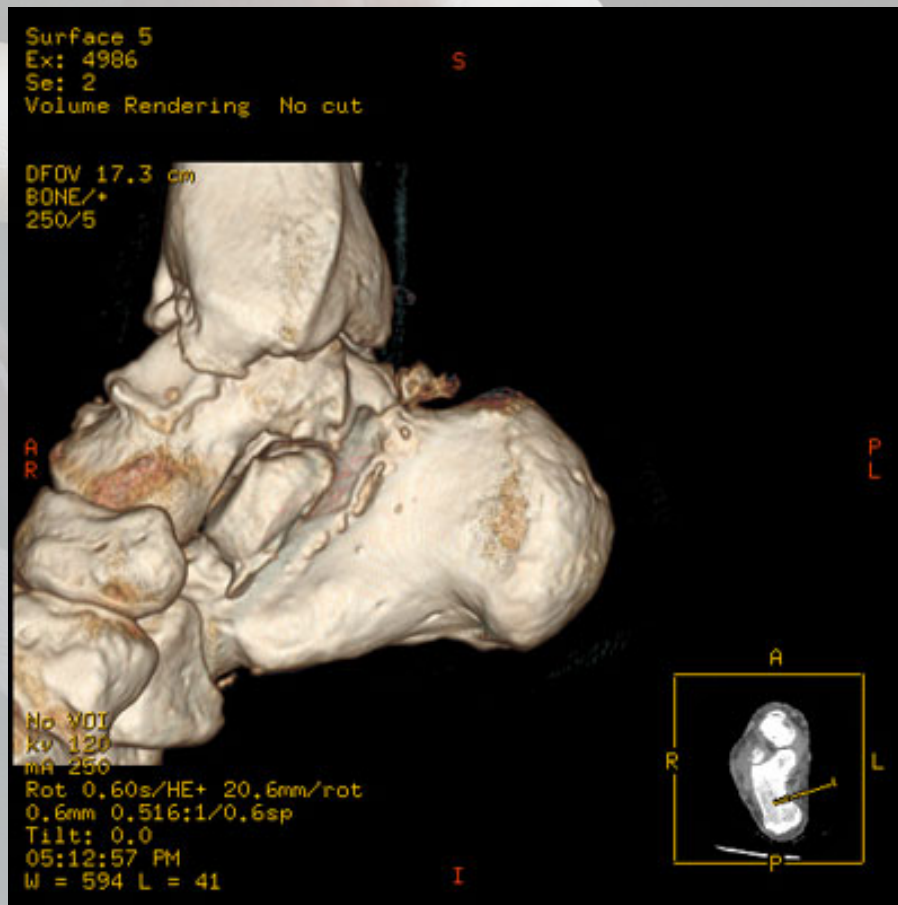


# Posterior Impingement



- Less common
- Posterolateral Impingement:
  - Natural Result of full weight bearing in maximal plantar flexion
  - Test: plantar flexion sign (press behind lateral malleolus and hyperflex)
  - Most often Os trigonum
    - DD: Acute ankle injury
  - Posteromedial Impingement:
    - Usually soft tissue (Capsule, Posterior Tibiotalar Ligament (PTTL), Flexor tendons)
    - DD: FHL Tendinitis

# Articular Surface Defects



- Arthroscopy is the best way of visualising and treating articular surface defects.

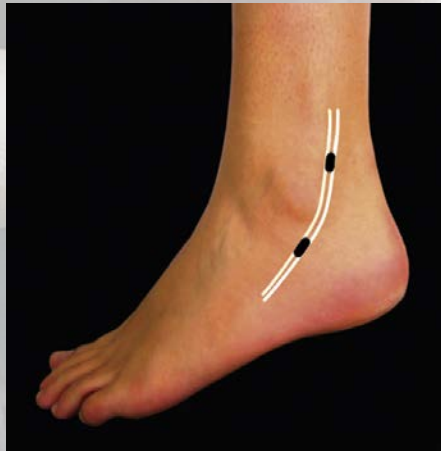

# Outcomes

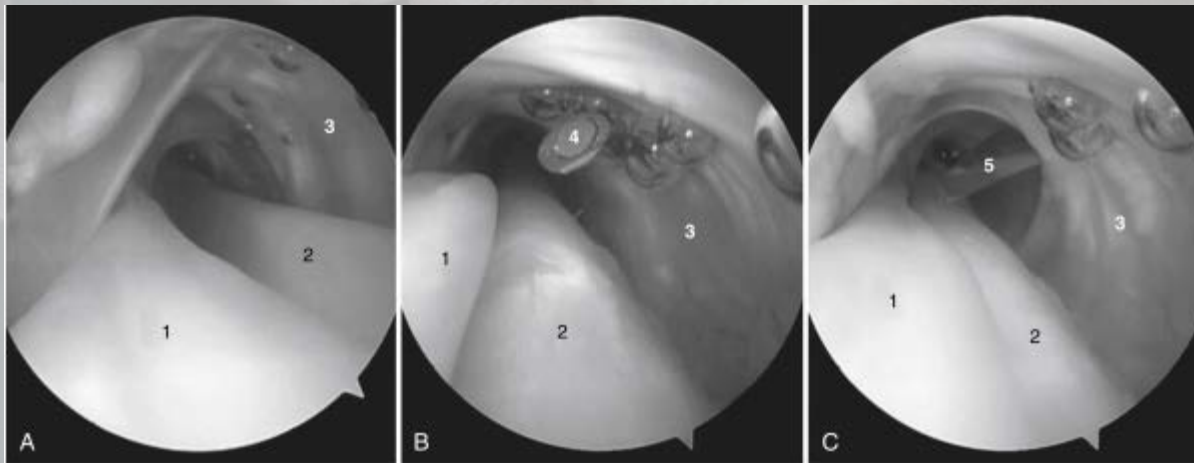


- The degree of osteoarthritic changes is a better prognostic factor than size and location of spurs
- Excellent or good results
  - In 90% without joint space narrowing
  - In 50% with joint space narrowing
- Van Dijk, Am J Sports Med, 1997

# Tendoscopy - Peroneal Tendons

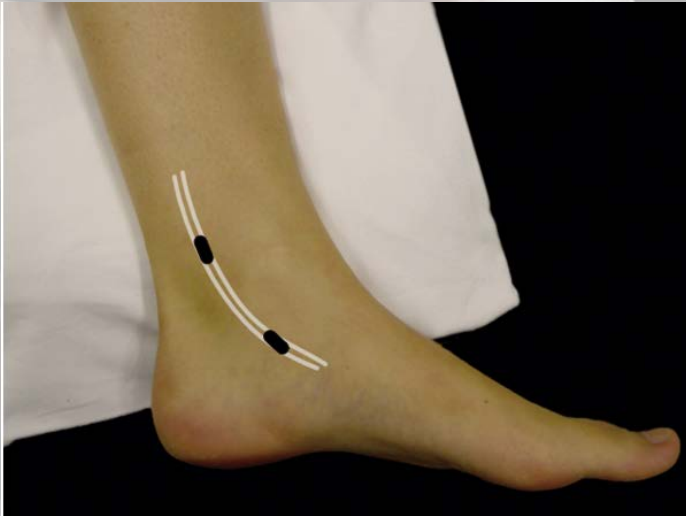


- Calcified deposits
- Tendinitis
- Endoscopic peroneal tendon groove deepening (difficult, iatrogenic tendon injuries)



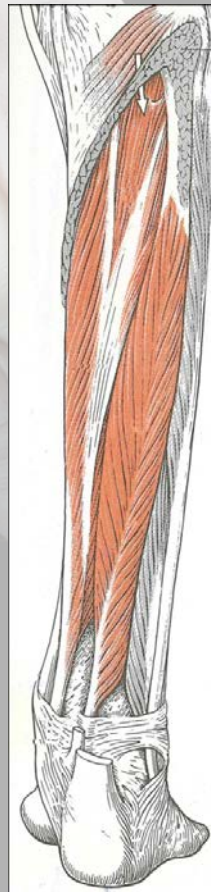
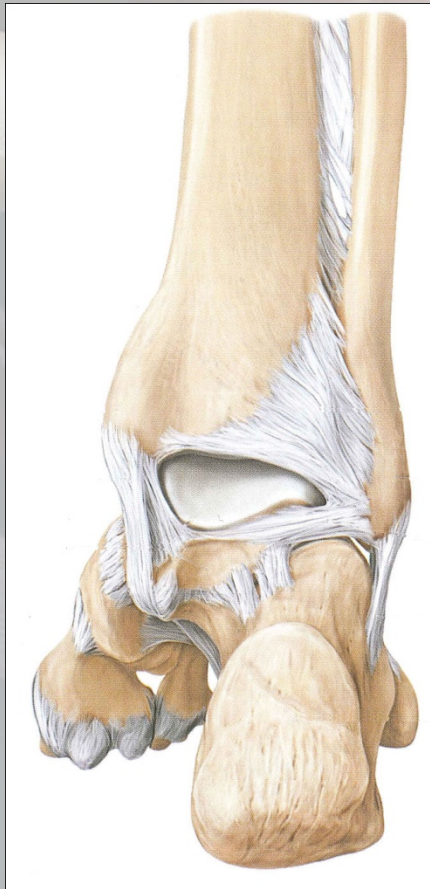


# Tendoscopy – Tibialis Posterior



- Start with distal portal
- Tendon sheath relatively thin behind medial malleolus - Be sure to be in the right sheath

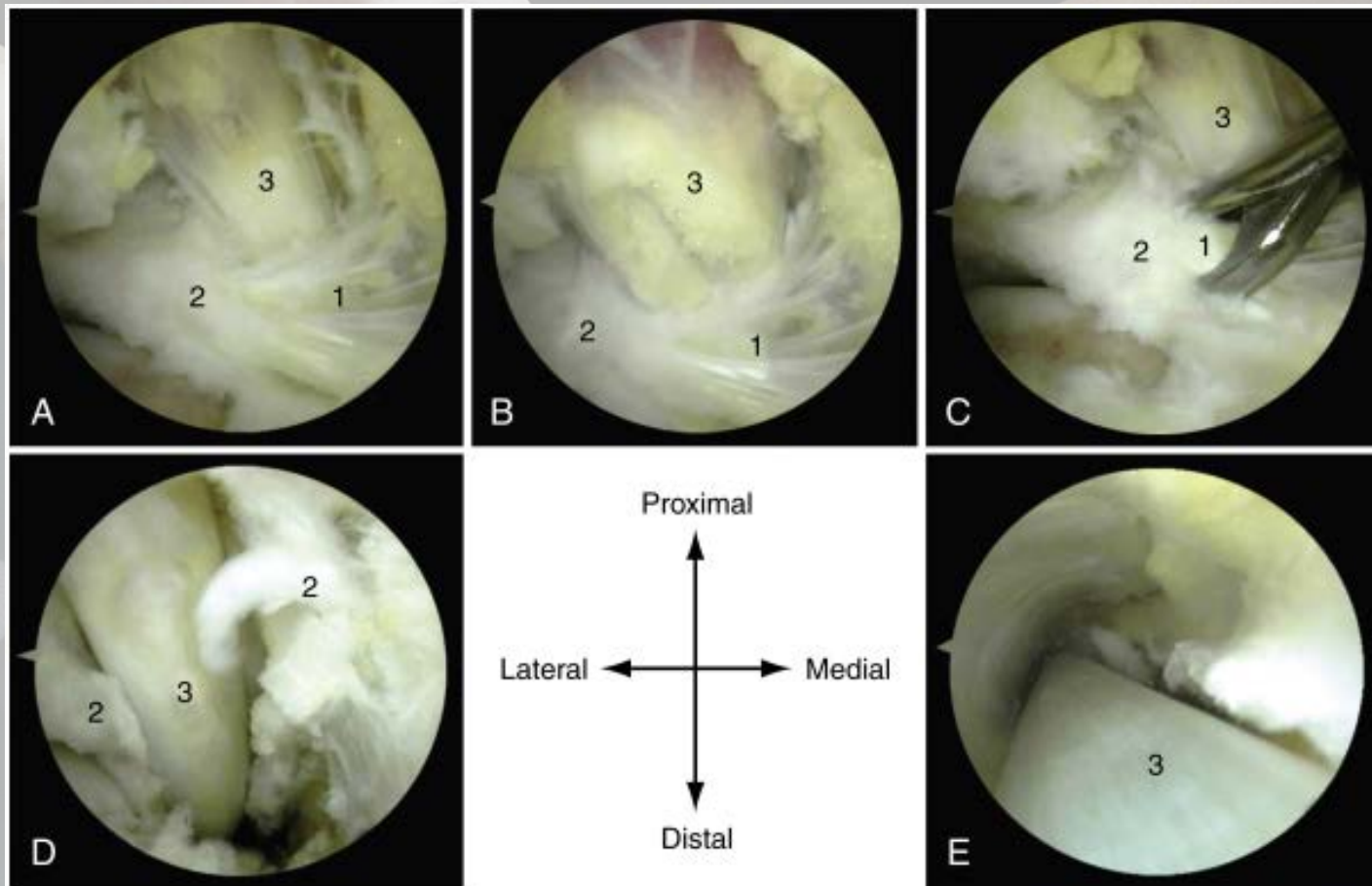
# FHL Tendoscopy



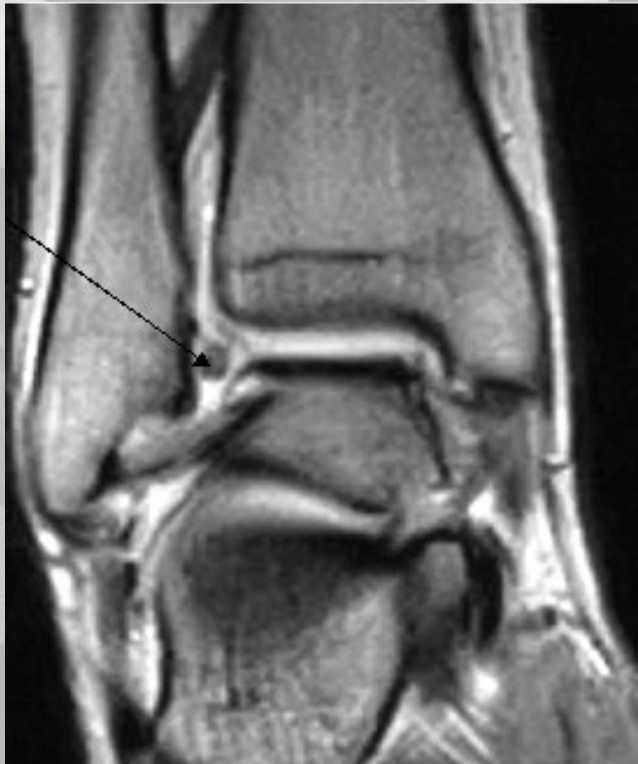- Dancer's tendinitis
  - Surgical intervention:
    - Os trigonum removal
    - Tendon debridement
- Insertions at os trigonum:
  - PTFL, Talocalcaneal Ligament, Flexor retinaculum



# FHL Tendoscopy



# Loose Bodies



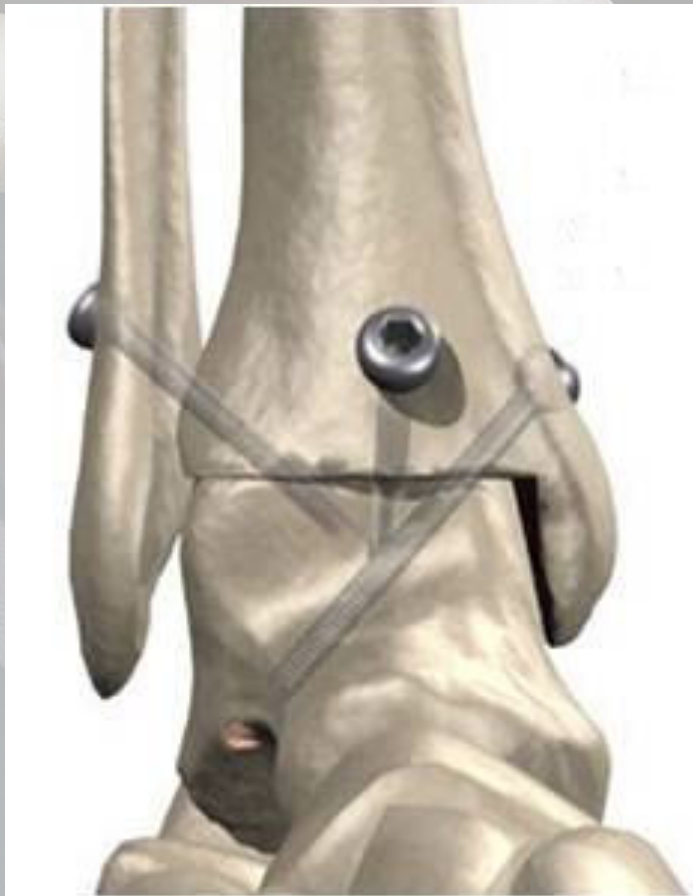- Primary and secondary osteoarthritis can be treated arthroscopically.
- Cheng and Ferkel (87) in 1998 showed that arthroscopic debridement for ankle and subtalar degenerative disease can provide an interim alternative to arthrodesis or ankle replacement, with removal of impinging osteophytes and loose bodies being treated effectively with arthroscopy.



# Osteophytes

- Pre Op 3-D CT Takao M et al, 2004
- 77% good or excellent results with Grade 1 disease
- Plain lateral X-Ray insufficient

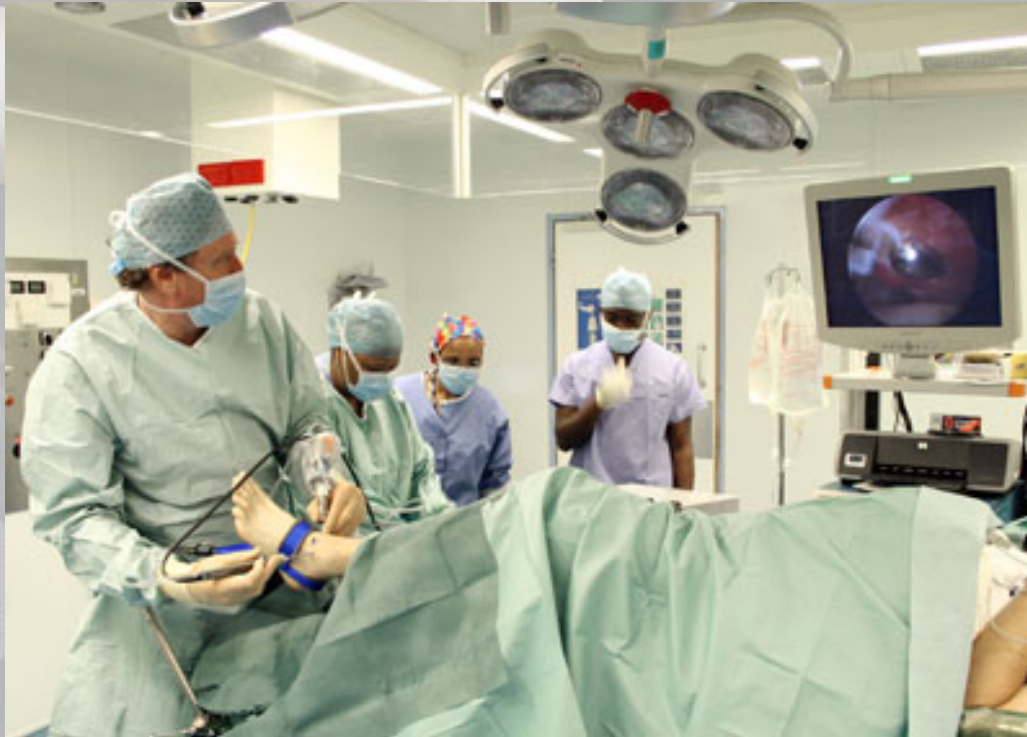# Ankle fusion



- Prepare joint arthroscopically
- Fuse joint with cannulated screws (6.7 mm)

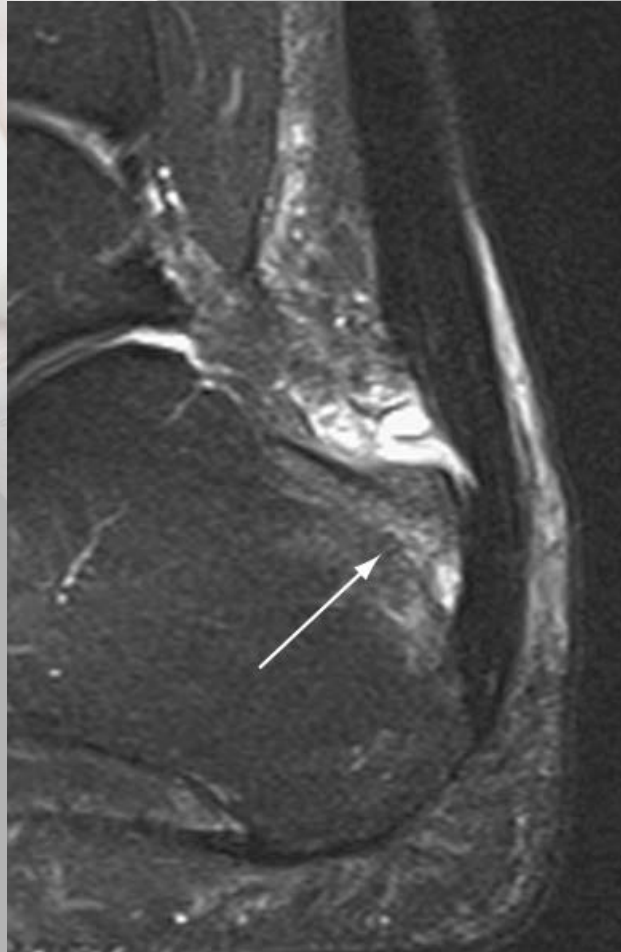


# Theatre Set-Up



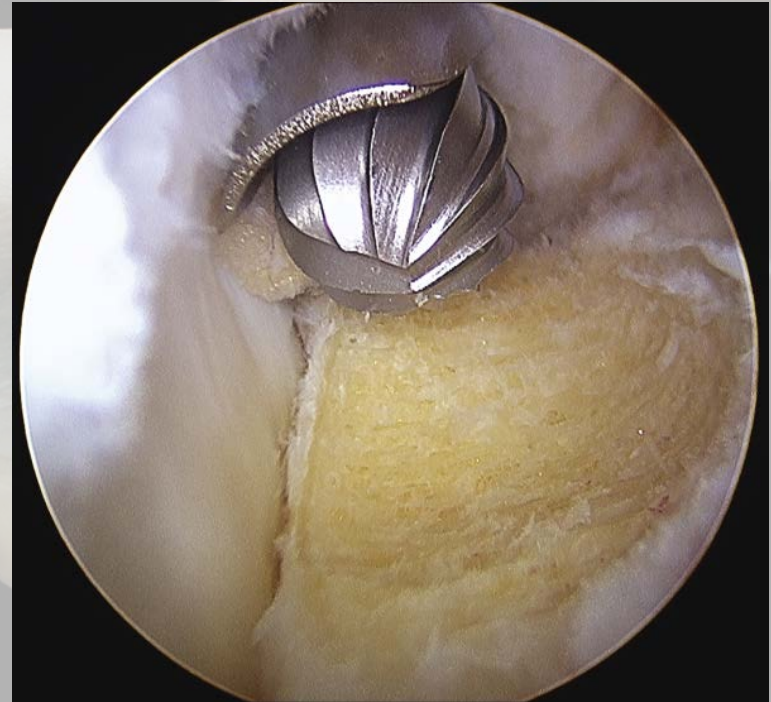
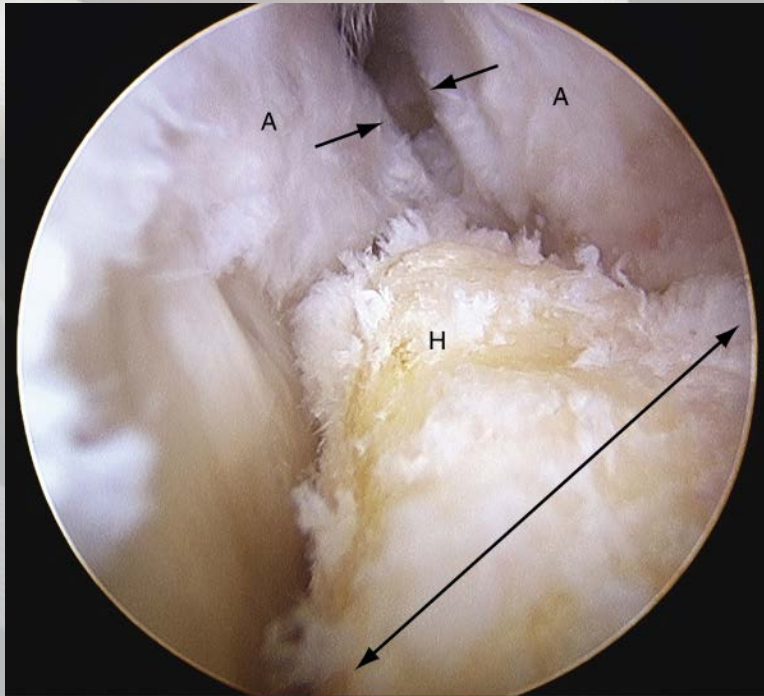
- Posterolateral Irrigation
- Large Joint Shavers
- Image Intensifier
- Large Fragment AO Cannulated Screws

# Haglund's Deformity





# Haglund's Deformity



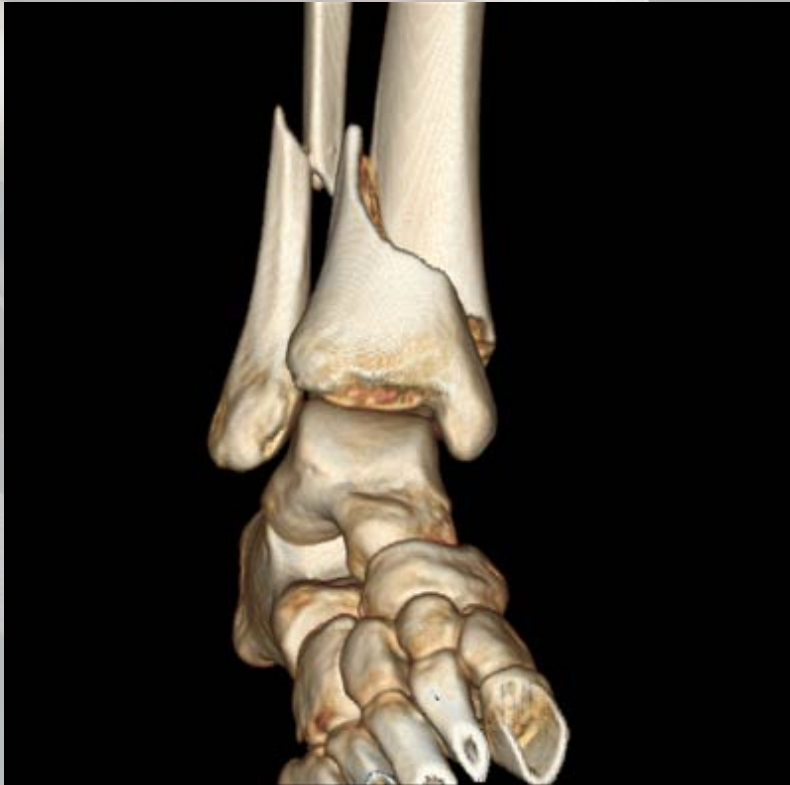# Ankle Fracture



- Articular damage in 89%
- 73% had OCD and 81% had syndesmosis disruption.
- Conclusion:
  - Moderate Evidence level
  - Own practice pre-op MRI and scope if indicated



# Ankle Fractures



- There have been numerous recent publications regarding the role of ankle arthroscopy in the diagnosis and treatment of combined intra-articular fractures of the ankle.
- The author's experience is that it allows a more accurate pre-operative assessment of the articular surfaces, removal of chondral or osteochondral loose fragments and removal of clot and early arthrofibrotic tissue, producing faster rehabilitation and better outcomes. This is supported by Ono A et al (88) in July 2004 with a series of 105 ankles.
- Ankle arthroscopy can also be used to treat poor results following standard fixation techniques, treating previously undiagnosed osteochondral lesions and syndesmotic injuries and arthrofibrosis (89).

# Chondral Lesions

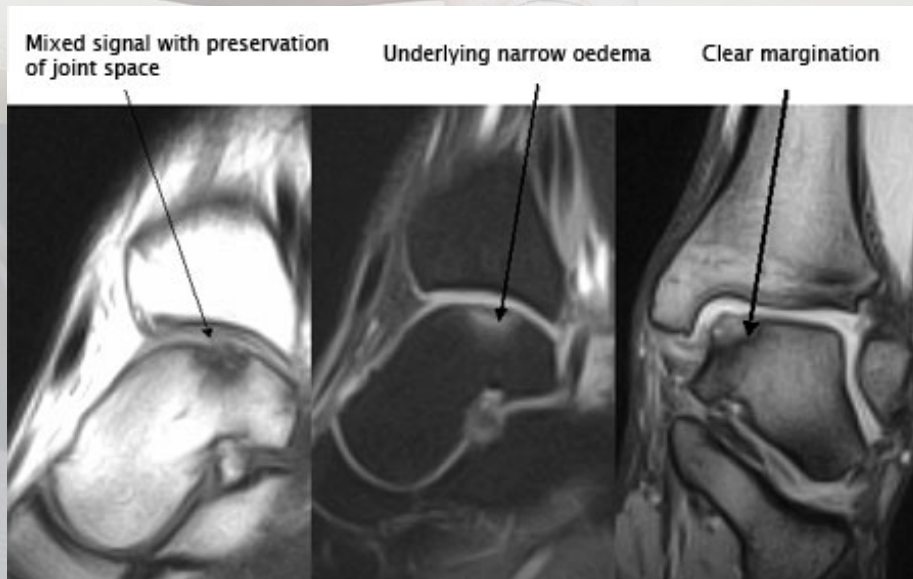
- Chondral lesions are usually caused by a sprain or by an RTA with direct compression of the articular cartilage. The pathologies range from blistering to full thickness flap tears. These lesions are frequently missed because of normal XR in A/E. If such lesions are suspected, then ankle arthroscopy is the only sure way to diagnose them with a full examination of anterior and posterior compartments required.
- Arthroscopic surgery is straightforward resecting chondral flaps to stable base and drill exposed bone to encourage vascular invasion and fibrocartilage formation.
- Ankle arthroscopic debridement and lavage parallels that of arthroscopic treatment of DJD in other joints.



# OCD

- Debridement,
- Abrasion
- Drilling
- Microfracture
- Autologue Cartilage Transfer
- Autologous Chondrocyte Transfer
- Allogen (Biomatrix)

# Osteochondral Lesions of the Talus - OLT



- Osteochondral lesions of the talus as such were first described in 1856 by Monroe (36) but Konig (37) coined the term 'osteochondritis' when he found similar pathology elsewhere in the body and thought the aetiology was osteonecrosis. Kappis (38) in 1922 first applied the term osteochondritis to the ankle joint.



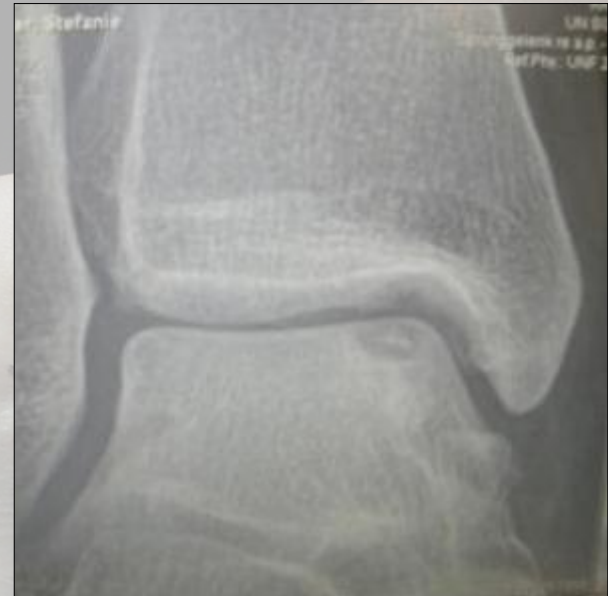# OCDs

- **Indications:**

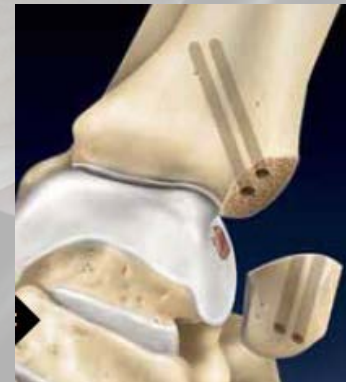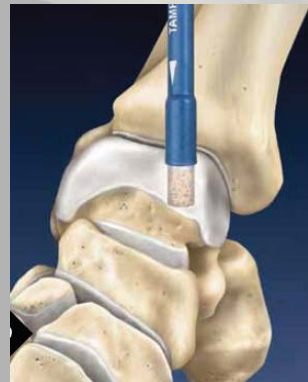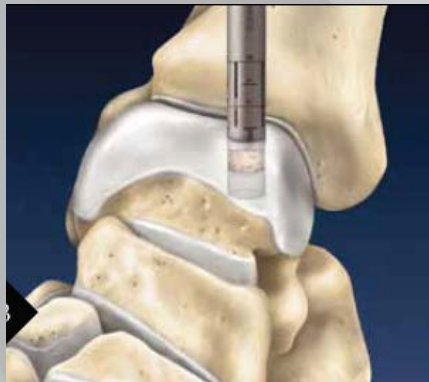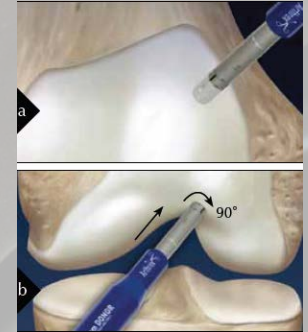
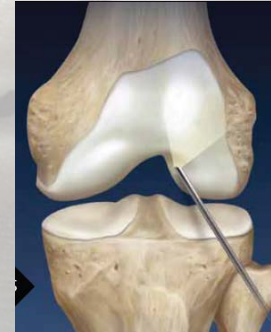
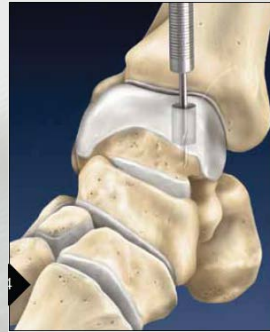
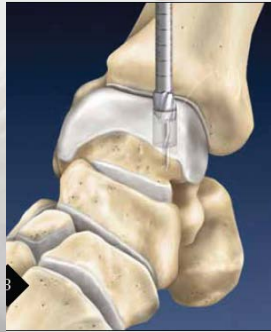
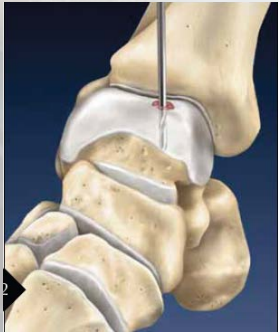
- OCDs of the talus
- Early stage of OCD
- Bone Cysts

- **Features/Benefits:**

- Removal of unstable cartilage
- Burr/ Microfracture underlying bone
- Removal of defect under arthroscopic visualization
- Defect can be filled with autograft bone
- Can use high precision instrument (aiming guide/drill guide with depth stop)

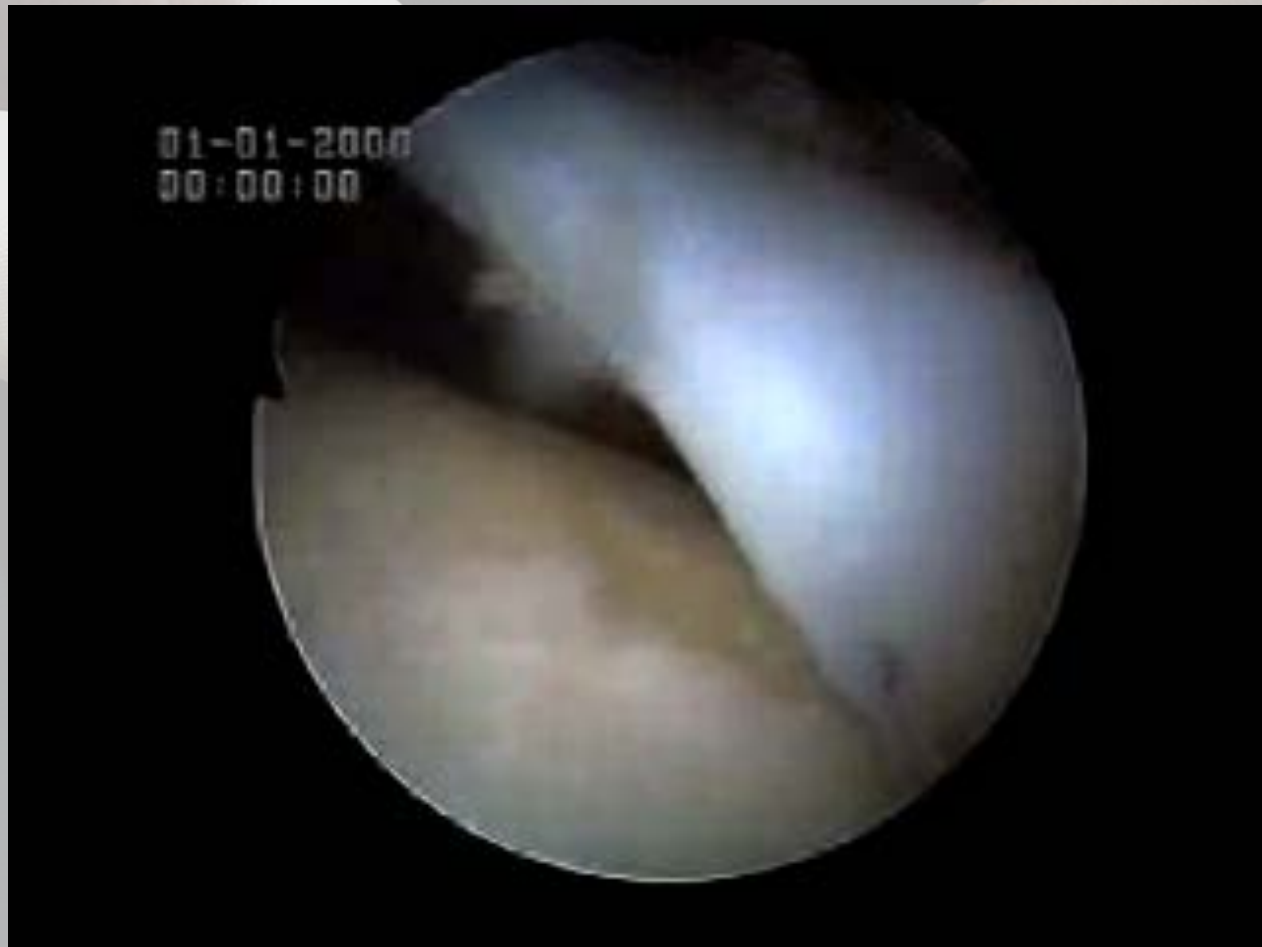

# OATS – Osteochondral Autograft Transfer System

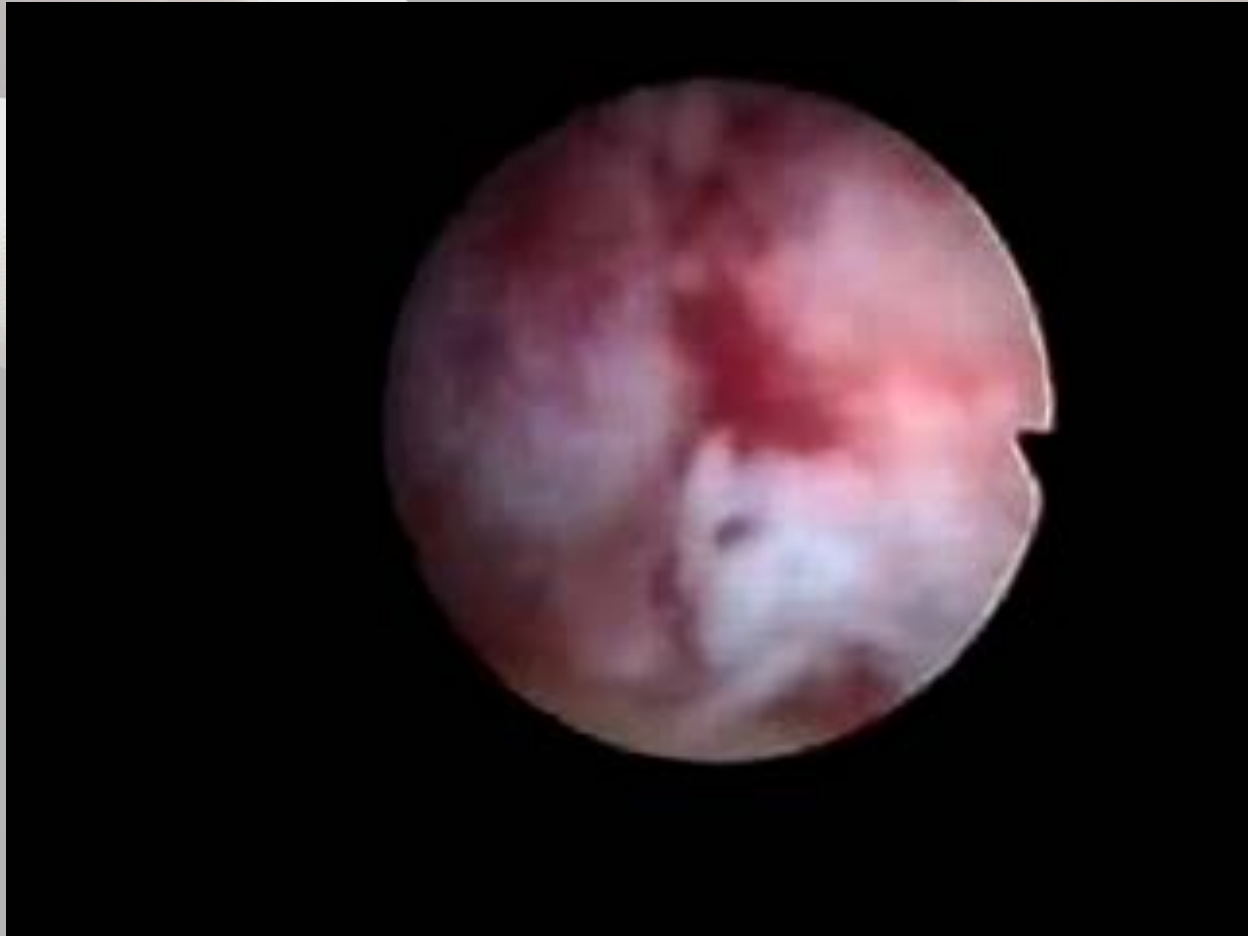



# Video: Meniscoid bands

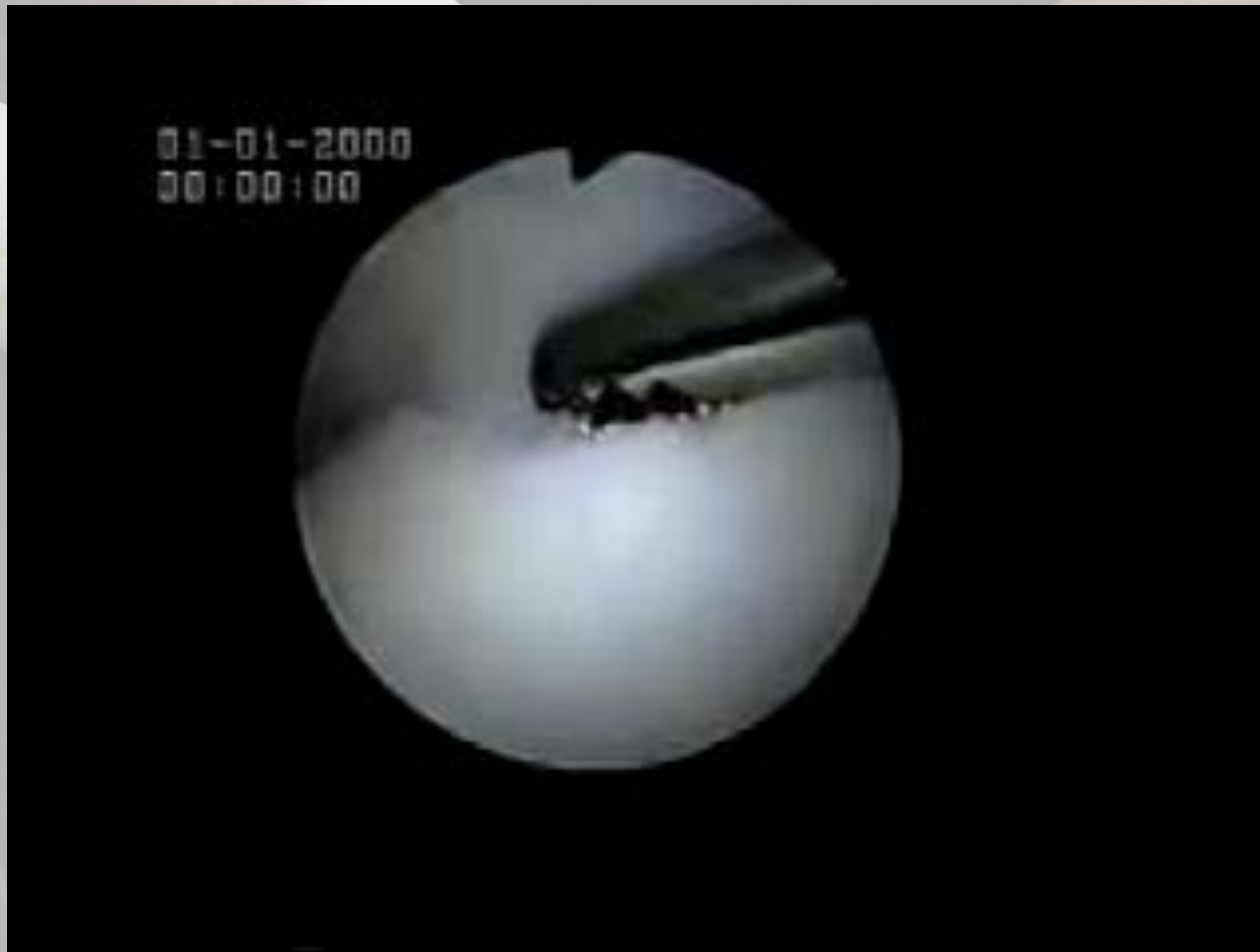

# Video: Synovial Disease





# Video: Osteochondral Defects



# www.ankle-arthroscopy.co.uk

## Ankle Arthroscopy

- HOME
- PATIENTS' SITE
- SURGEONS' SITE
- VIDEOS
- ABOUT SIMON MOYES
- CONTACT
- LINKS



### Ankle Arthroscopy Website

Simon Moyes specialises in keyhole – or arthroscopic – surgery. This site is dedicated to conditions of the ankle joint that are treated by Simon. Patients can find all the information they need about some of the more common ankle problems, while surgeons and medical professionals can find an up-to-date medical resource for those involved in or studying ankle arthroscopy.

#### Quick Search

Go straight to the specific page you are looking for by using the drop down below:

#### Patients' Site

An outline of common ankle problems, with information about how the injury / ailment feels, what surgery is likely and the projected recovery time.  
[Click here for the Patients' Site](#)

#### Surgeons' Site

An in-depth resource about all aspects of ankle arthroscopy for medical professionals. Contains highly-referenced documentation of the procedure, citing examples from the early history to current findings.  
[Click here for the Surgeons' Site](#)

Simon Moyes | Medico-legal

© Simon Moyes 2007 | sitemap | disclaimer



A close-up photograph of a hand gently holding a foot. The hand is positioned on the left, with fingers wrapped around the foot. The foot is on the right, with the heel and arch visible. The skin tones are light. The background is dark and out of focus. A semi-transparent grey rectangle is overlaid on the image, and the text "Thank You" is centered within it in a black serif font.

Thank You